Surgery Within and Around Critical White Matter Tracts

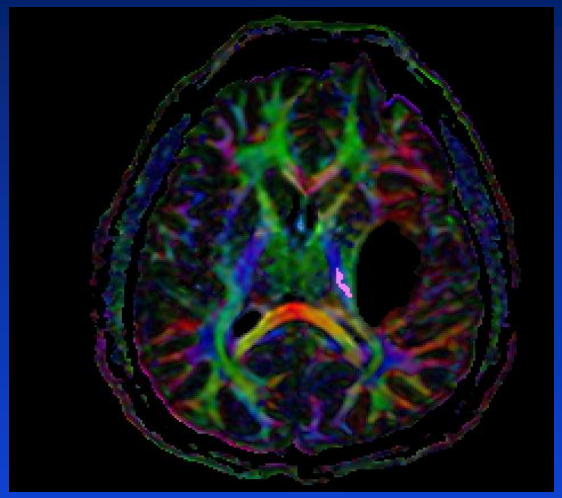

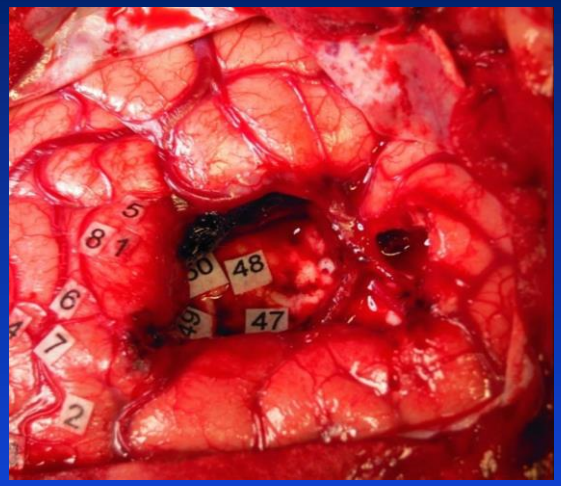

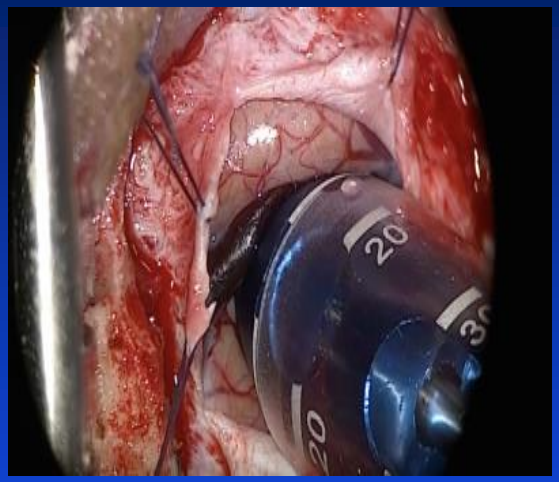

Kaisorn L. Chaichana, M.D.

Assistant Professor of Neurosurgery, Oncology, and Otolaryngology-Head & Neck Surgery

Mayo Clinic Florida, Jacksonville, FL

Subcortical Space

- Area of the brain below the cortical surface
- Critical white matter tracts
- Critical gray matter regions
- Traditional techniques to access these regions can be associated with significant morbidity

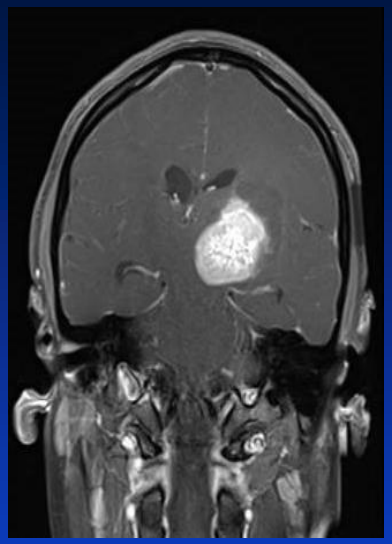

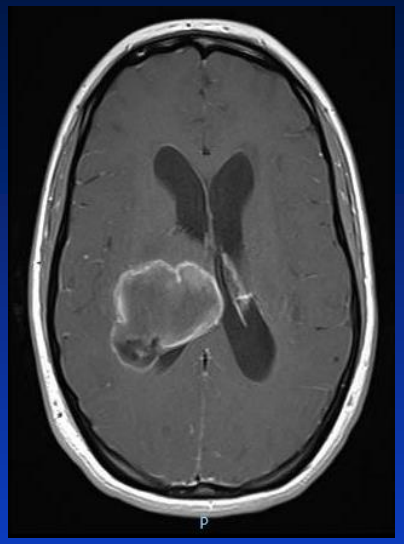

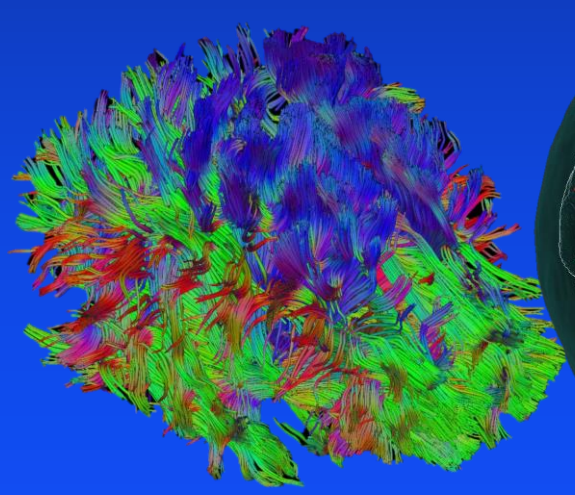

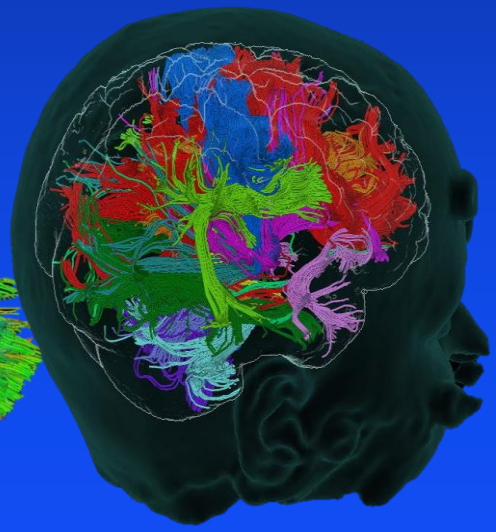

Critical White Matter Tracts

- 3 different types of tracts
  - Commissural
  - Projection
  - Association

WHITE MATTER TRACT	FIBER CATEGORY
Corona Radiata/Internal Capsule (CR/IC)	Projection
Optic Radiations (OR)	Projection
Superior Longitudinal Fasciculus (SLF)	Association
Inferior Longitudinal Fasciculus (ILF)	Association
Uncinate Fasciculus (UNC)	Association
Inferior Fronto-Occipital Fasciculus (IFO)	Association
Cingulate Fasciculus (CNG)	Association
Corpus Callosum (CC)	Commissural
Anterior Commissure (AComm)	Commissural

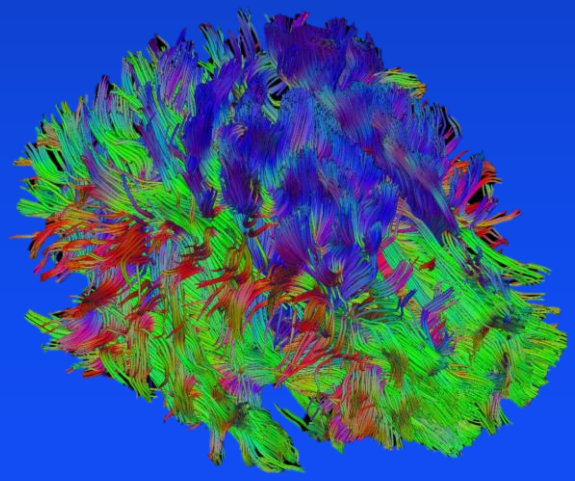

Corticospinal Tract

- Principle projection fibers of the cerebral hemisphere
- Largest projection fiber tract
- Consists of:
  - Corona radiata superiorly
  - Classic V-shaped capsule at level of basal ganglia
  - Crus cerebri in cerebral peduncle

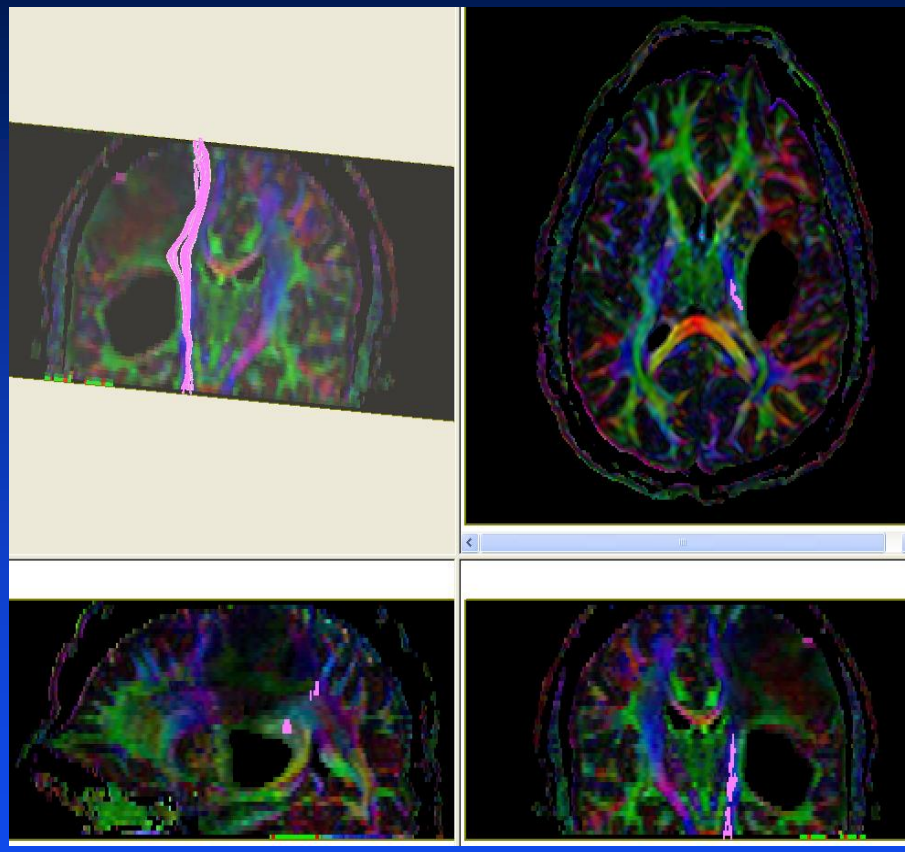

Superior Longitudinal Fasciculus/Arcuate Fasciculus

- Lateral to ventricles and centrum ovale
- Indirect: SLF I-III, SLF-tp; Direct: AF
- Dorsal Stream
- Connects portions of frontal lobe with occipital and temporal areas
- Disruption can cause deficits in:
  - Language (phonetics/articulation/repetition)
  - Motor coordination
  - Visual spatial perception

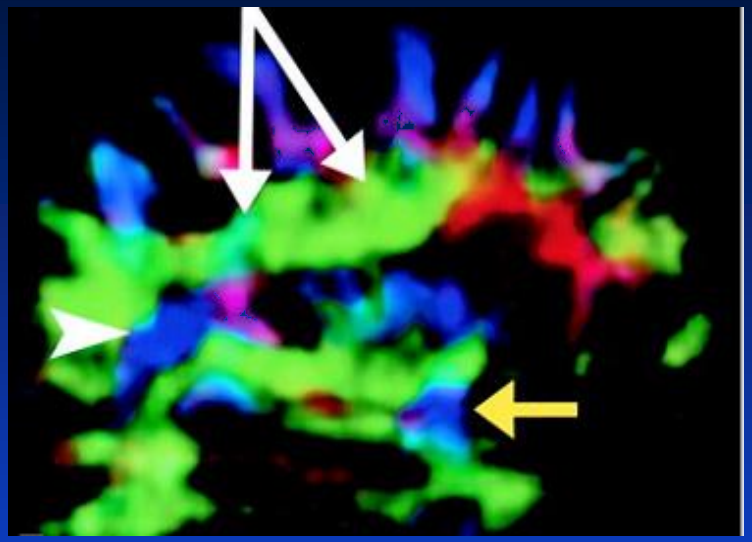

Inferior Frontal-Occipital Fasciculus

- Connects orbital and frontopolar regions with ventromedial occipital cortex
- Ventral Stream
- Under insular region, deep to SLF, at level of external capsule
- Disruption can cause deficits in:
  - Language (semantics)

Inferior Longitudinal Fasciculus

- Connects temporal and occipital lobes
- Runs at level of optic radiation
- Fibers blend with the IFOF
- Involved in:
  - Object Recognition
  - Visual Agnosia
  - Prospagnosia

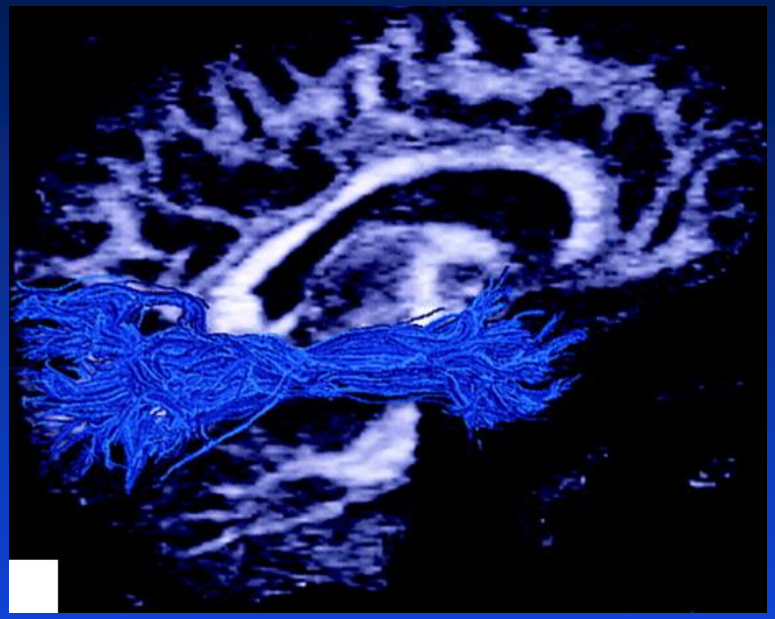

Other Tracts

- Left Frontal Aslant Tract
- Subcallosal Fasciculus
- Uncinate Fasciculus
- Superior Frontal-Occipital Fasciculus
- Middle Longitudinal Fasciculus

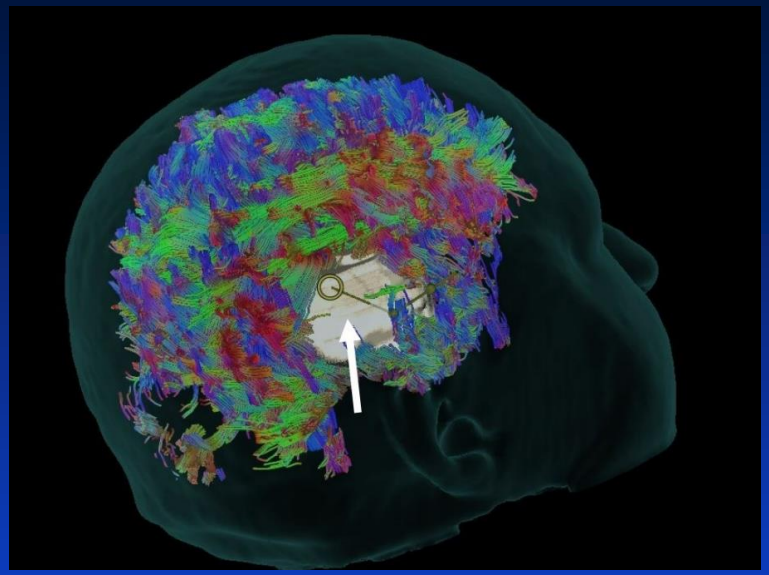

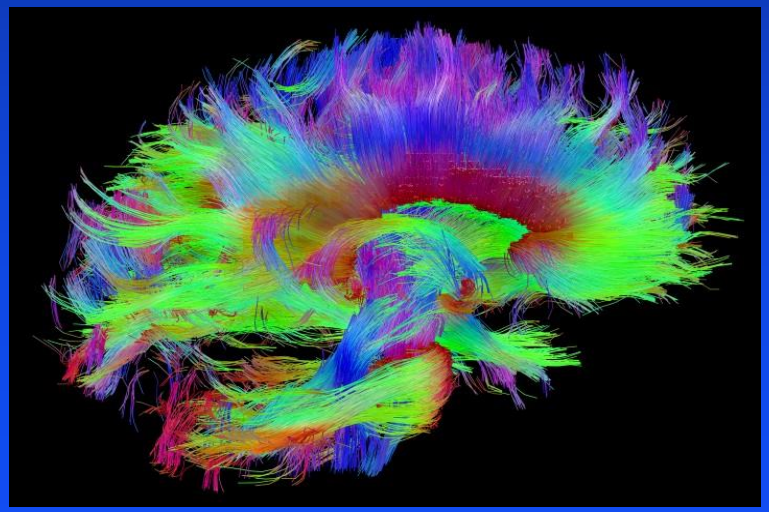

Why Does It Matter?

- Neurological exam not sensitive for detecting deficits
- Functional status is critical
- Every patient prior to surgery
  - Neuropsych testing
  - Goals of care discussion
  - DTI +/- fMRI
  - High resolution T2 MRI (axial/coronal)

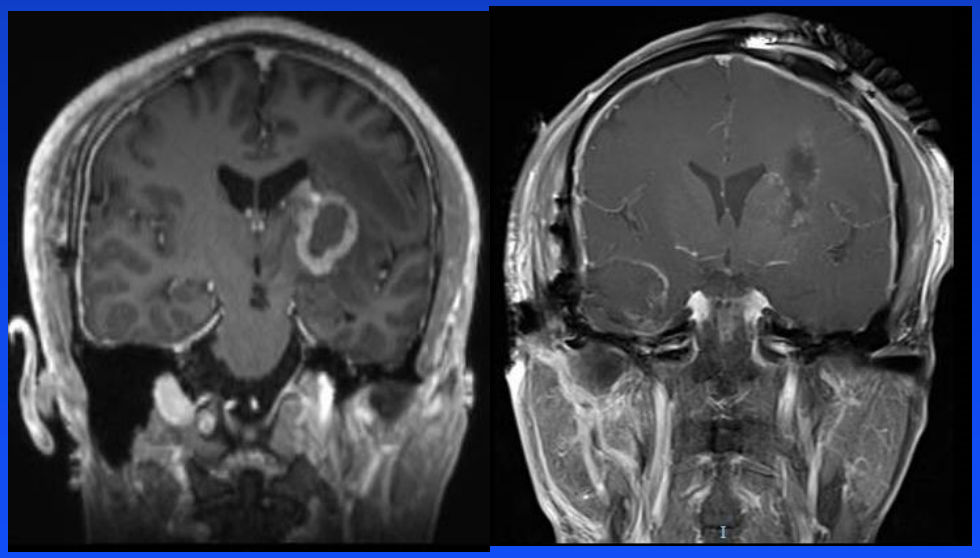

General Approaches to Subcortical Brain Tumors

- Goal is to preserve eloquent cortical areas and white matter tracts
- Two methods:
  - 1) Identify and avoid these areas (i.e. awake mapping)
  - 2) Displace these tracts (i.e. parafascicular approach)

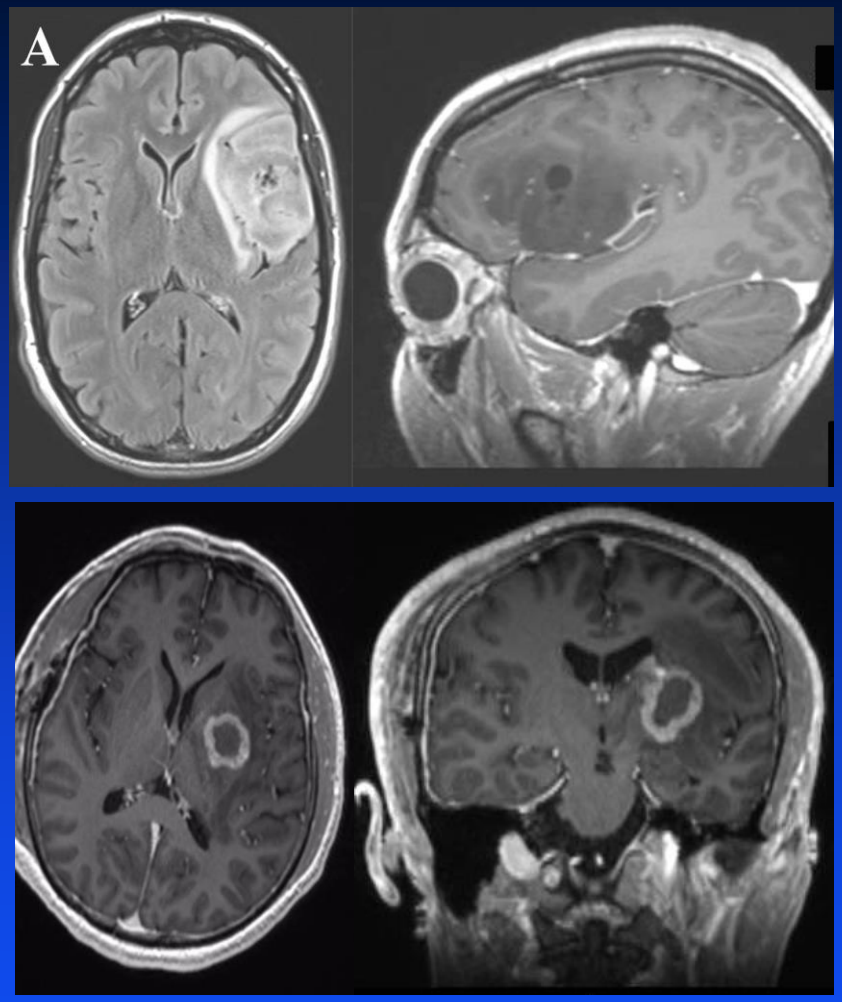

Chaichana et al, Neuro Oncol, *16 (1), 1113, 2014*
Jackson et al. J Neurosurg, 78 (6), 588, 2017
Iyer et al. J Neurosurg, in press

Awake Brain Mapping

- Critical elements
  - Resection based on onco-functional boundaries
  - Real time evaluation of neurological function
  - Need to know what tracts/functions you are looking for
- fMRI
  - Coupling between neurological activity and blood flow
  - Cannot determine critical functions
  - Sensitivity (37.1%), Specificity (83.4%) (Kuchsinki et al, 2015)
- DTI
  - Diffusion of water along tracts
  - Diffusion properties altered with tumors
  - No agreement in construction (Pujol et al, 2015)

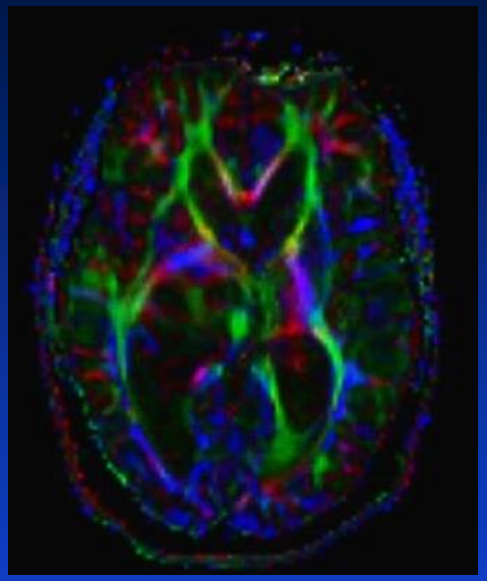

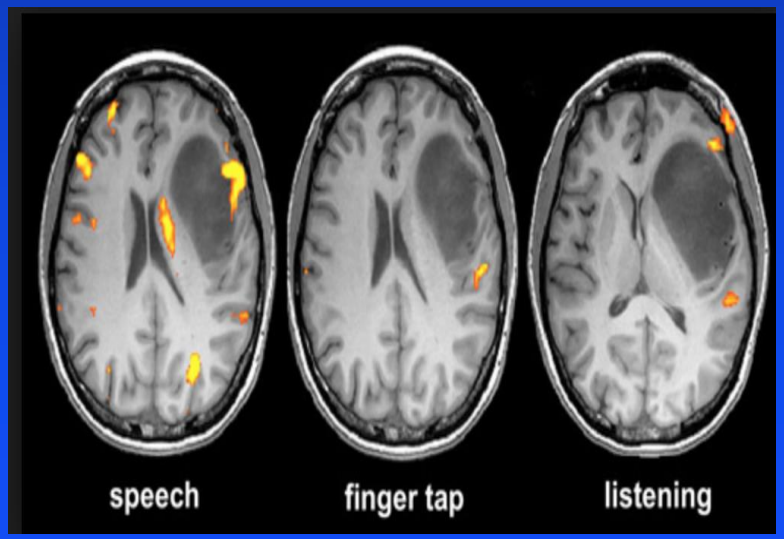

Awake Brain Mapping Protocols

- Prior to surgery
  - Neuropsych testing
  - Goals of care discussion
  - DTI +/- fMRI
  - High resolution T2 MRI (axial/coronal)
- During surgery
  - Asleep-Awake-Asleep Anesthesia
  - Ultrasound, Navigation
  - Mapping
  - +/- iMRI
- After surgery
  - SLP/PT
  - Neuropsych testing (3-6 months)

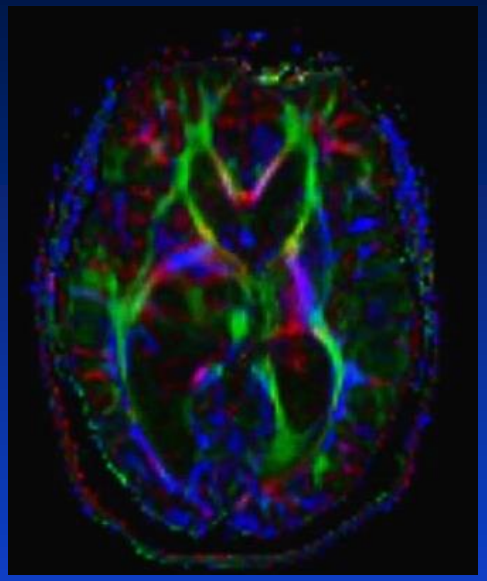

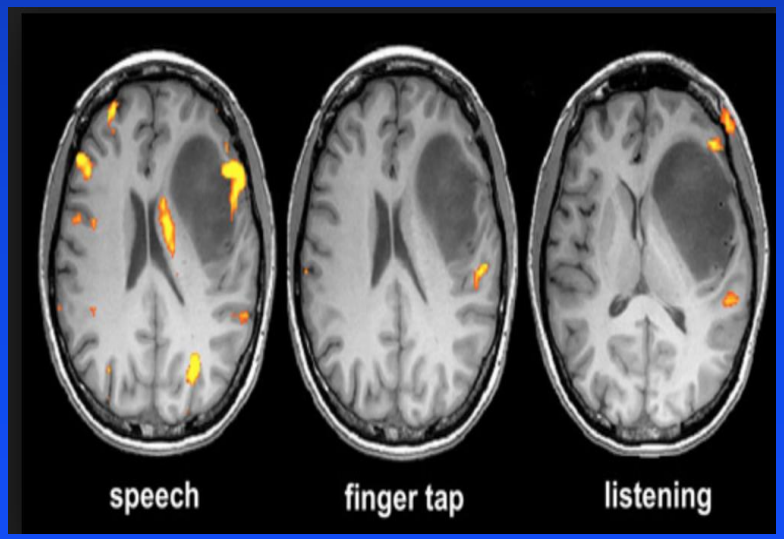

Awake Brain Mapping – Case 1

- CC: seizures
- HPI: 45 yo RH female college professor who presented with partial seizures
- PE: intact, neuropsych normal
- Concerning areas
  - Cortical: Broca's, premotor, motor
  - Subcortical: SLF/AF, IFOF (anterior limb), FAT, caudate

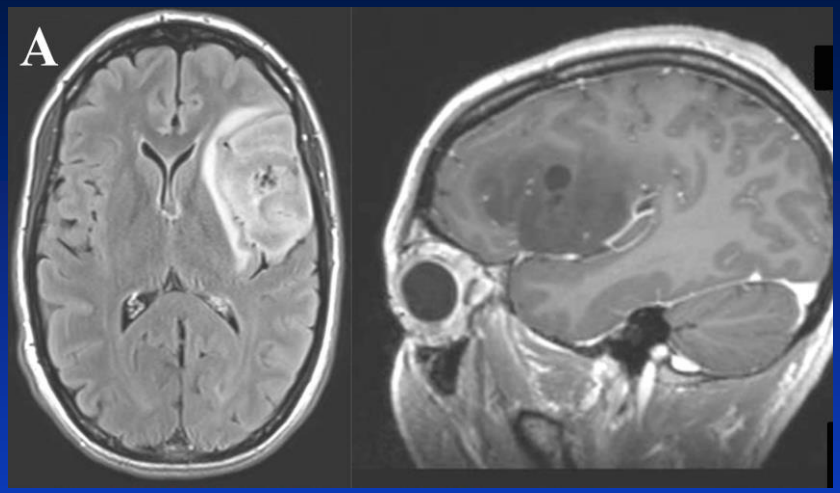

Chaichana et al, Approaches to Brain Tumors, Elsevier, 2018, in press

Awake Brain Mapping – Case 1

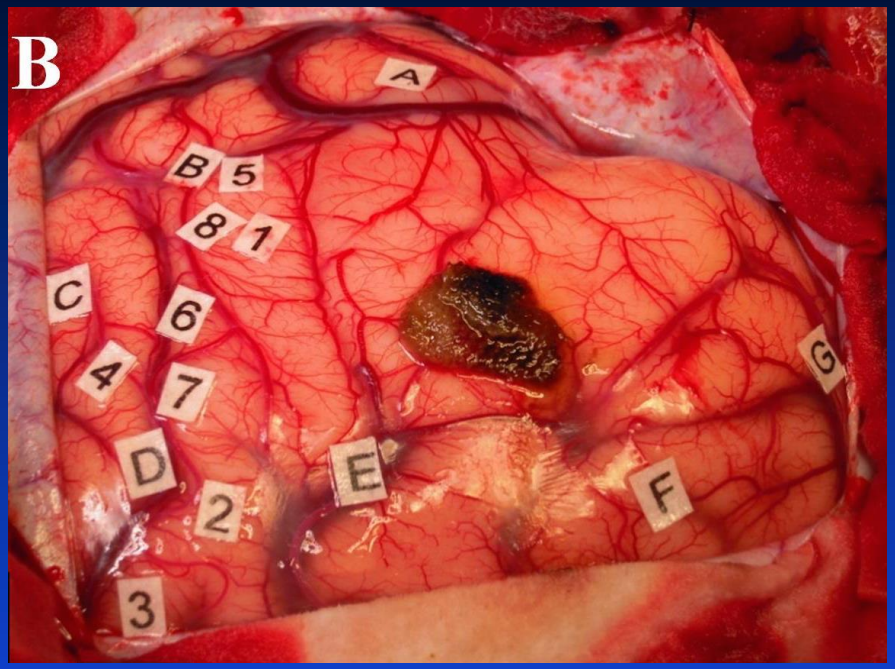

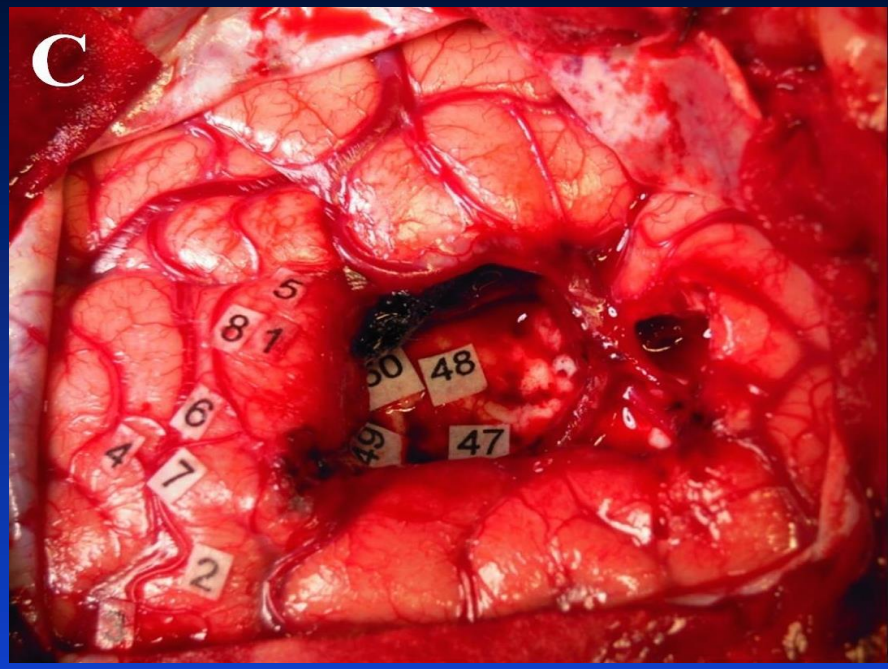

Letters – ultrasound projection of tumor
1, 5, 8 – motor cortex/Broca's (anarthria, facial twitching)
6, 7 – ventral premotor (articulation disturbances)
2, 3 – motor cortex (RH movement arrest)
4 – somatosensory (RH and face paresthesias)
47 – head of the caudate (perseveration)
48 – IFOF (semantic paraphasia)
49 – FAT (speech initiation problems)
50 – SLF (articulation)

Chaichana et al, Approaches to Brain Tumors, Elsevier, 2018, in press

Awake Brain Mapping – Case 1

- Pathology – IDH1+, 1p19q-
- Immediate postop – hesitancy with speech, dysarthria
- 2 weeks postop – intact exam
- 1 mo back to teaching
- 3 mo neuropsych – normal

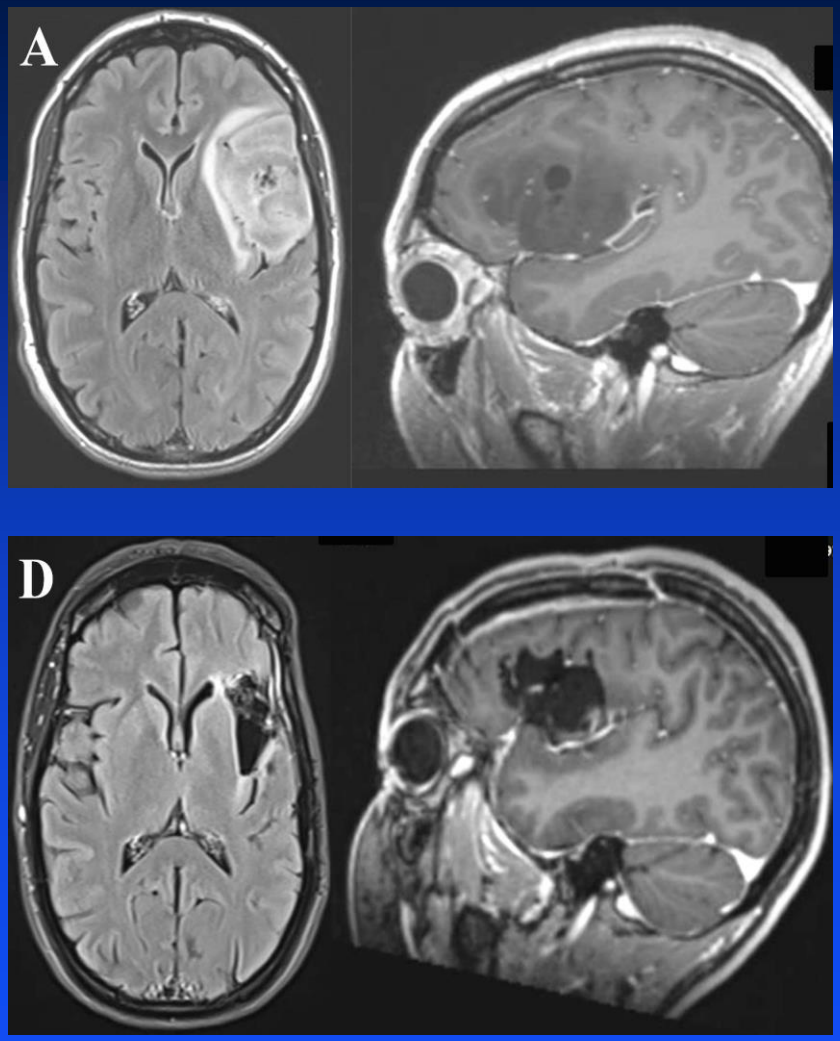

Chaichana et al, Approaches to Brain Tumors, Elsevier, 2018, in press

Awake Brain Mapping – Case 2

- CC: seizures
- HPI: 49 yo RH male business owner who presented with partial seizures
- PE: intact, neuropsych normal
- Concerning areas
  - Cortical: Wernicke's, motor
  - Subcortical: SLF (III, tp)/AF, IFOF

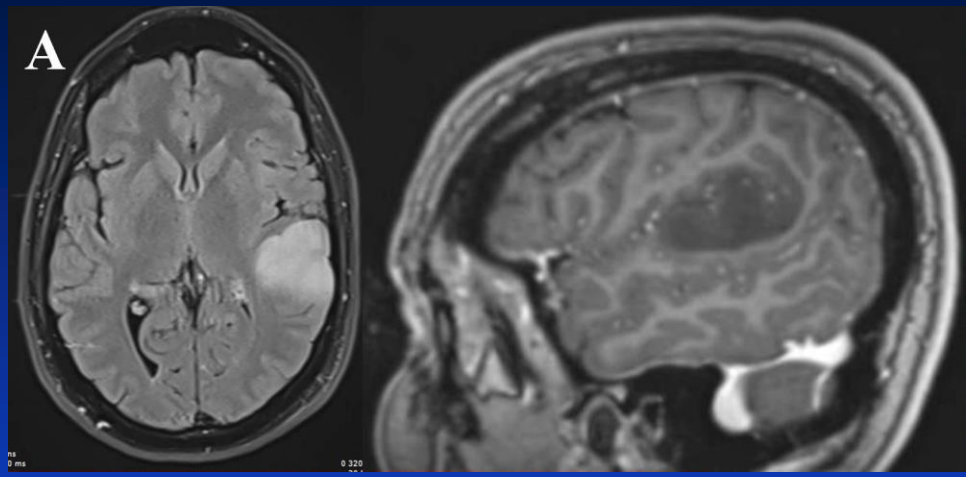

Chaichana et al, Approaches to Brain Tumors, Elsevier, 2018, in press

Awake Brain Mapping – Case 2

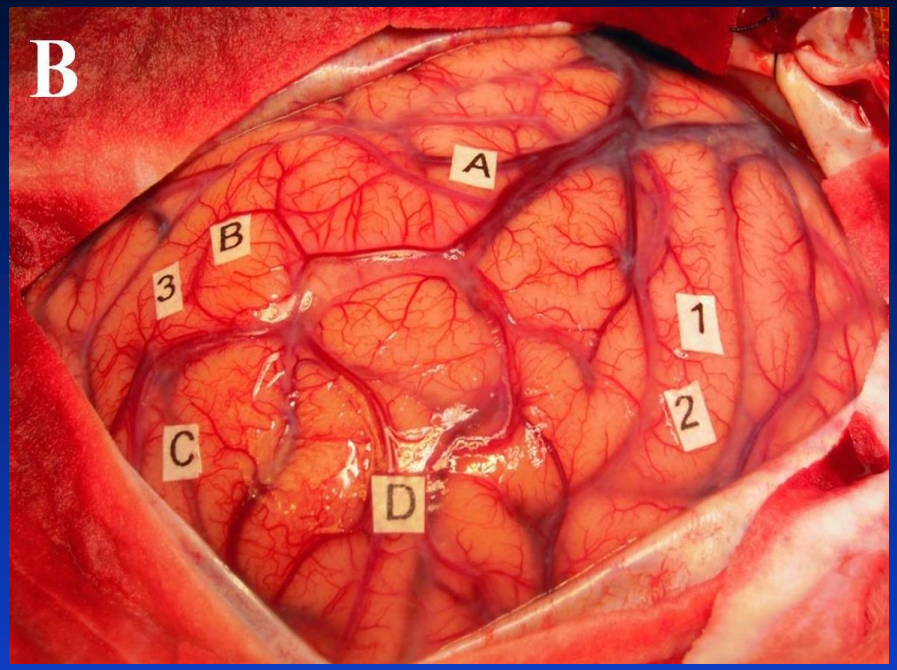

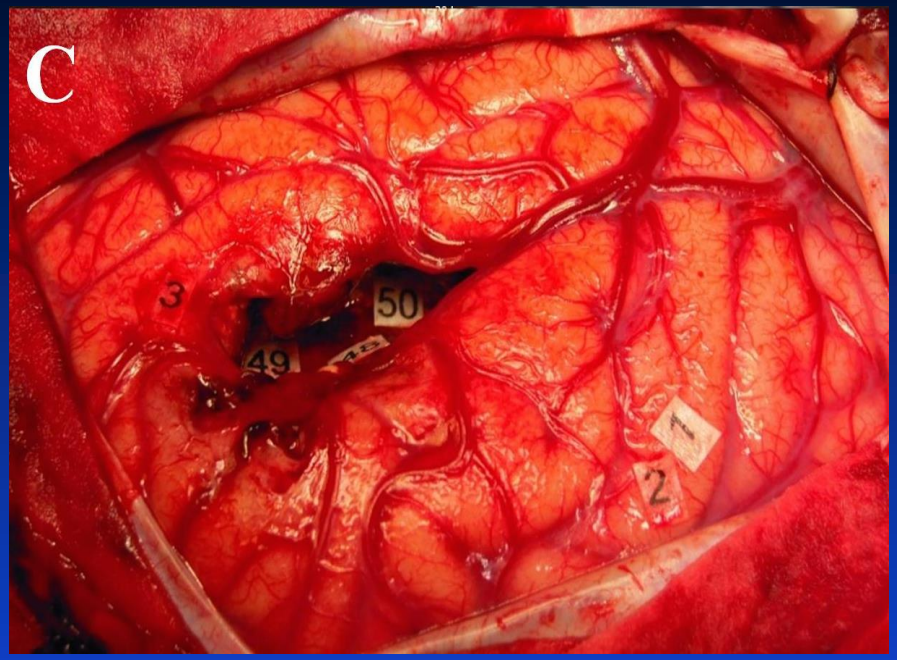

Letters – ultrasound projection of tumor
1, 2 – ventral premotor (articulation disturbances)
3 - complete anomia
48 – SLF (articulation difficulty)
49 – AF (phonological paraphasias, repetition)
50 – IFOF (semantic paraphasia)

Chaichana et al, Approaches to Brain Tumors, Elsevier, 2018, in press

Awake Brain Mapping – Case 2

- Pathology - IDH1-, 1p19q-
- Immediate postop – some comprehension difficulty
- 2 weeks postop – intact exam
- 1 mo – returned to work
- 3 mo neuropsych - normal

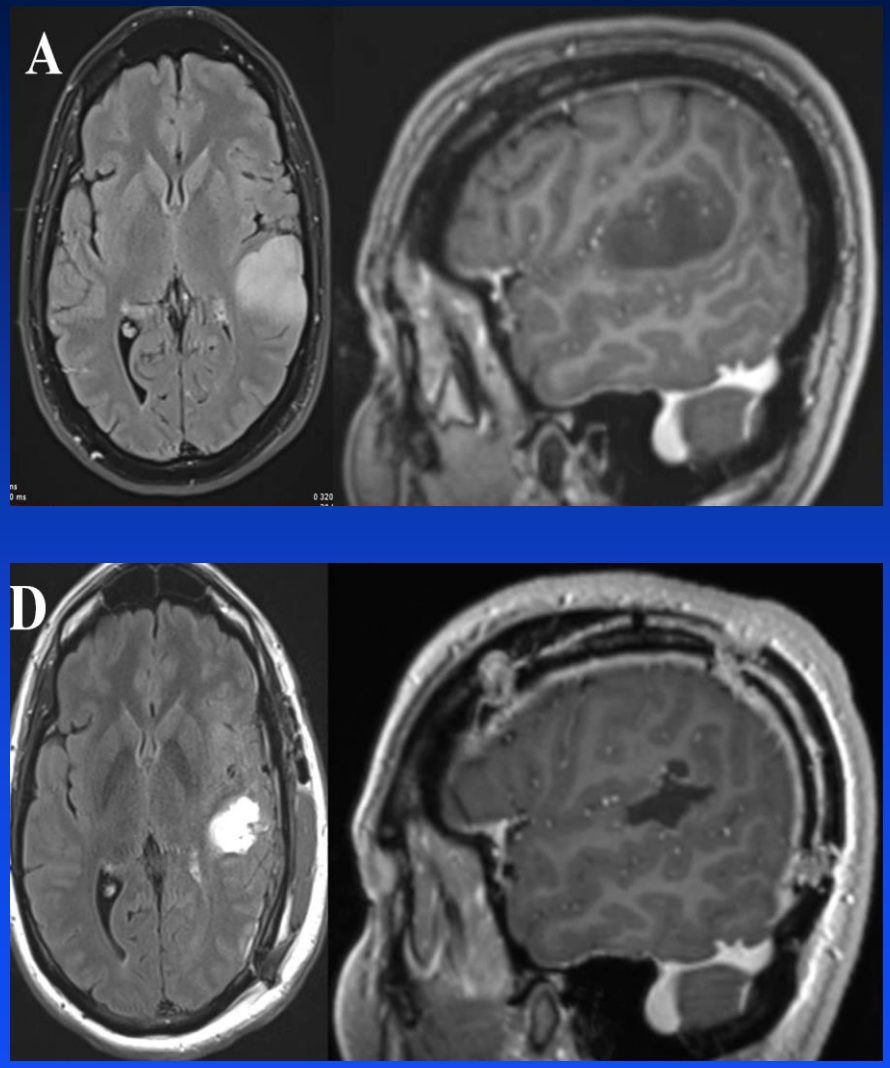

MAYO CLINIC

Chaichana et al, Approaches to Brain Tumors, Elsevier, 2018, in press

General Approaches to Subcortical Brain Tumors

- Goal is to preserve eloquent cortical areas and white matter tracts
- Two methods:
  - 1) Identify and avoid these areas (i.e. awake mapping)
  - 2) Displace these tracts (i.e. parafascicular approach)

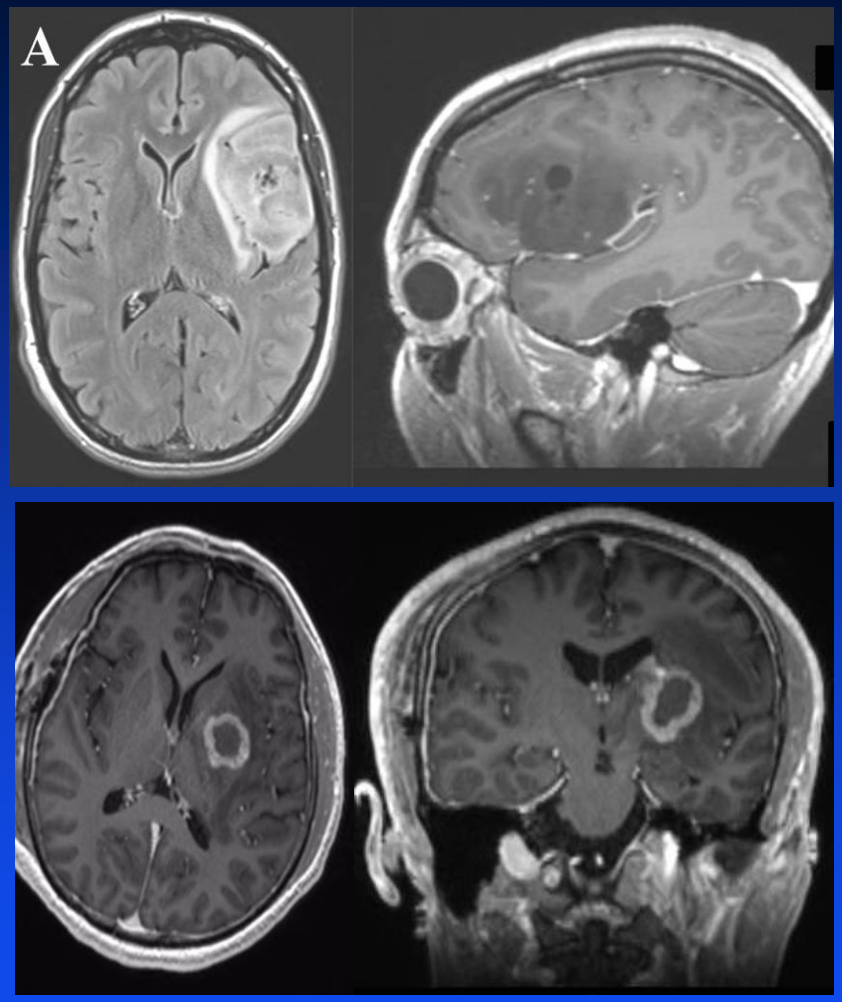

Chaichana et al, Neuro Oncol, *16 (1), 1113, 2014*
Jackson et al. J Neurosurg, 78 (6), 588, 2017
Iyer et al. J Neurosurg, in press

Traditional Approaches to Subcortical Brain Tumors

- Large craniotomy
- Extensive white matter dissection
- Use of fixed retractor systems
- Potential sources of injury
  - White matter dissection
  - Tissue creep
  - Repetitive entry into resection site
  - Ischemia induced by retraction

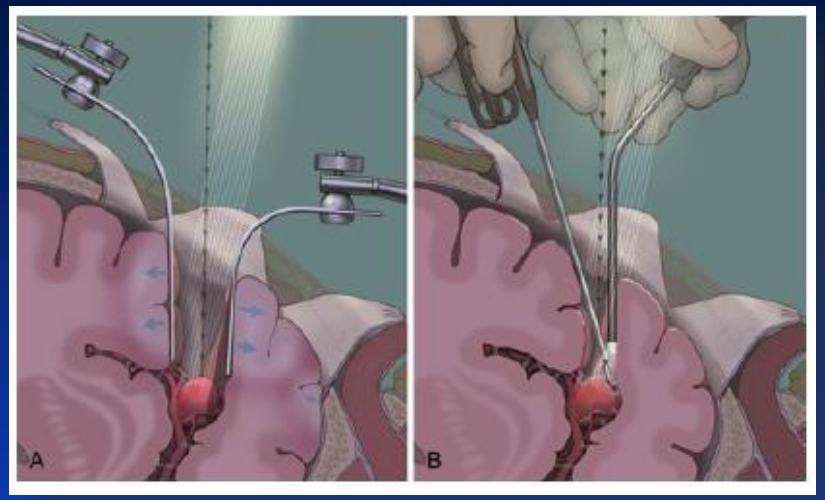

MAYO CLINIC

Spetzler et al, *J Neurosurg, 116, 291, 2012.*

Concept of Minimally Disruptive Approaches

- Trans-sulcal vs. Trans-gyral
- Displacement of white matter tracts (<15 mm)
- Tubular retractors
  - Circumferential retraction
  - Protected corridor for dissection and resection

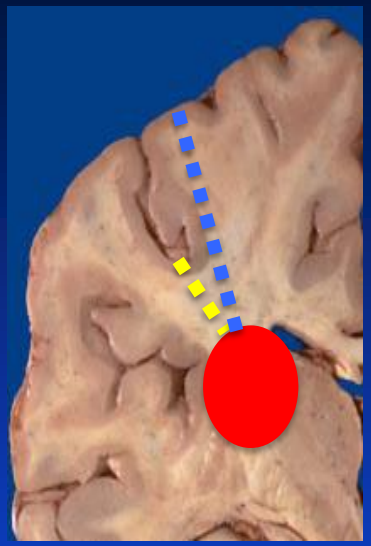

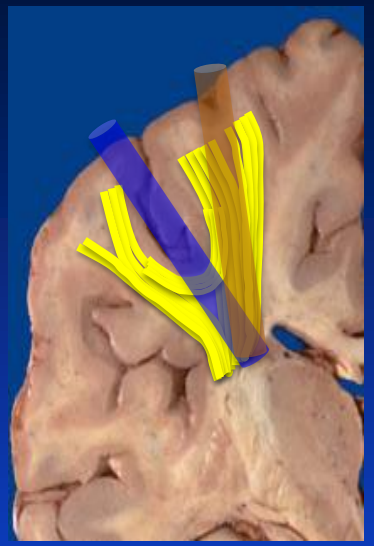

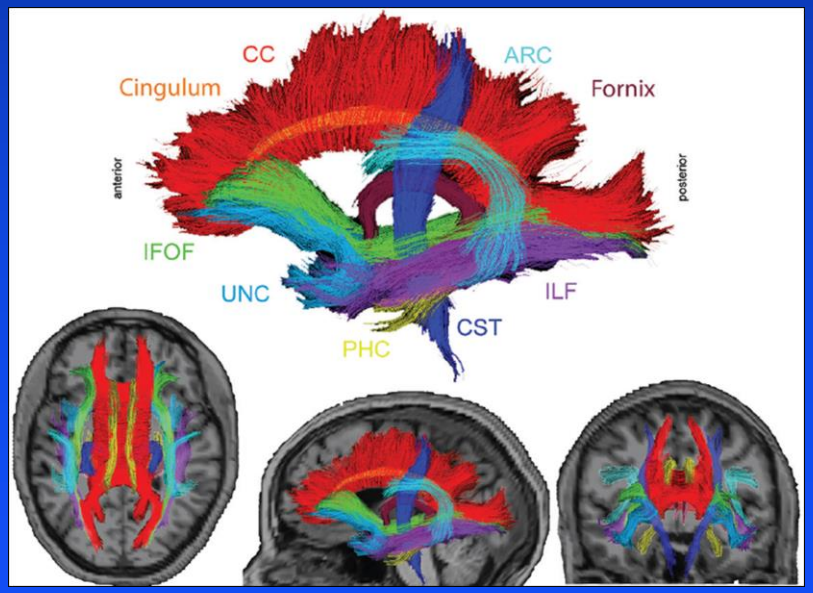

Chaichana et al, *Trans-Sulcal Approaches*, Elsevier, in press.

Use of Tubular Retractors is an Old Concept

J Neurosurg 69:301–306, 1988

The stereotaxic retractor in computer-assisted stereotaxic microsurgery

Technical note

PATRICK J. KELLY, M.D., STEPHAN J. GOERSS, B.S., AND BRUCE A. KALL, M.S.

Departments of Neurosurgery and Information Processing and Systems, Mayo Foundation and Mayo Medical School, Rochester, Minnesota

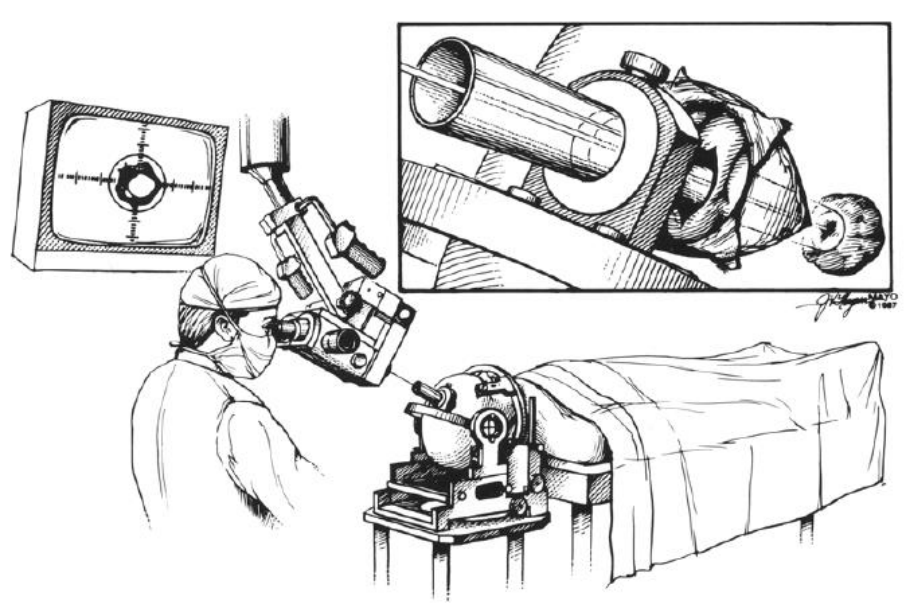

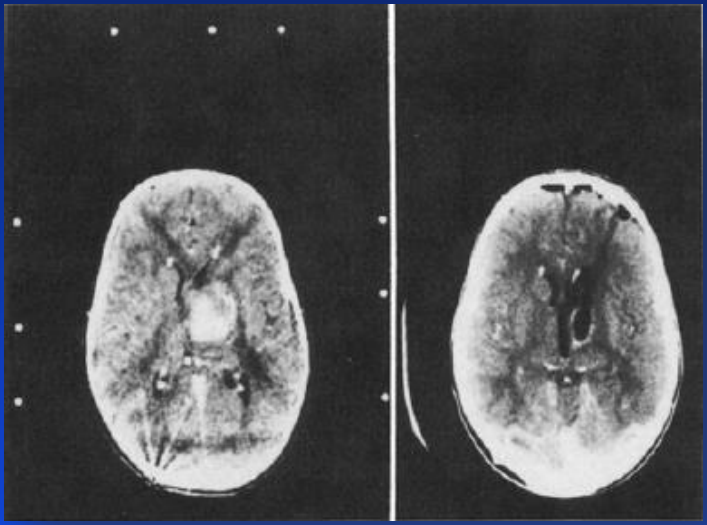

Kelly et al, *J Neurosurg, 69, 301, 1988.*

Variety of Tubular Retractors

- Peel-away catheters (12F, 14F, 17F)
- Viewsite™
- BrainPath™

Peel-Away Catheters

- Advantages
  No brain retraction
  Minimal collateral damage

- Disadvantages
  Requires endoscope
  Limited degree of freedom
  Limited number of instruments
  Hemostasis
  Cavity-based surgeries

Colloid Cyst with Peel-Away Catheters

- 22 year-old female with history of colloid cyst that increased in size on serial imaging from 3 mm to 8mm, with increase in headaches.
- Right frontal, trans-cortical approach

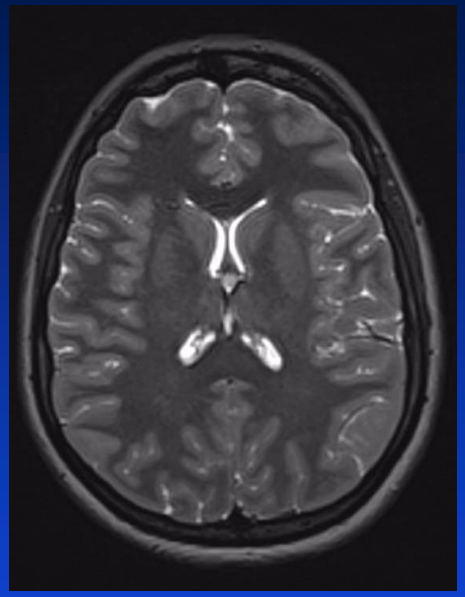

Colloid Cyst with Peel-Away Catheters



Colloid Cyst with Peel-Away Catheters

- Final pathology: colloid cyst
- Discharged to home on POD 1

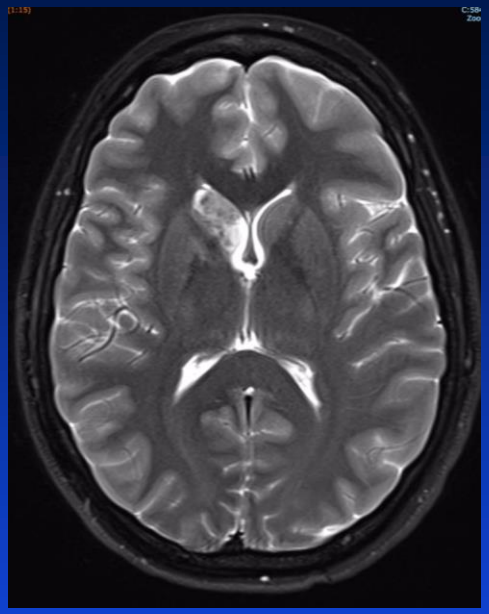

BrainPath™ Tubular Retractor

- Advantages
  Circumferential retraction
  Trans-sulcal or gyral
  Minimal collateral damage
  Microscope or exoscope

- Disadvantages
  Limited to 13.5 mm aperture
  Limited instruments
  Limited degree of freedom

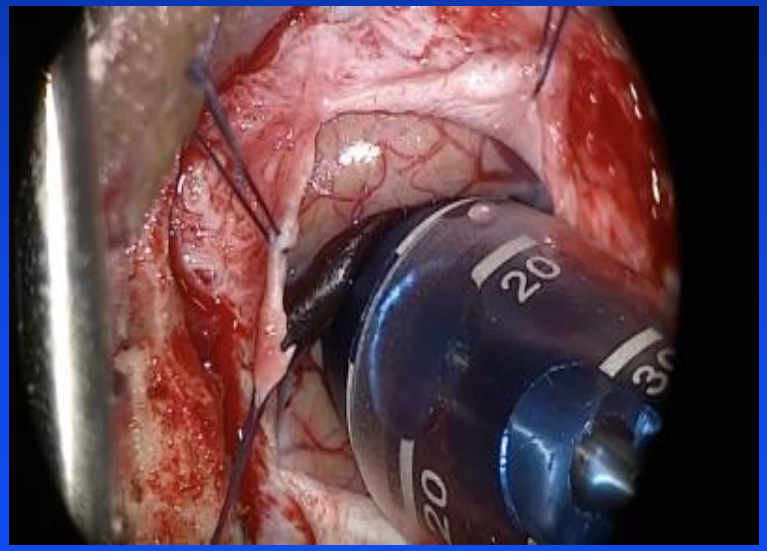

Exoscopic Visualization

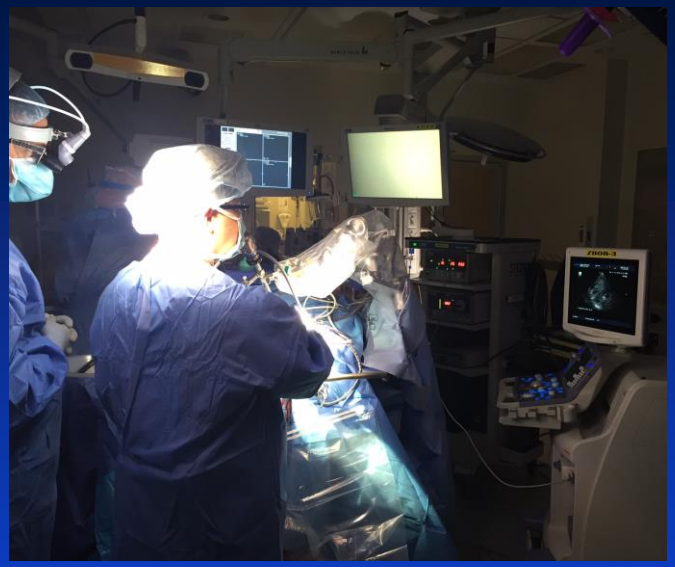

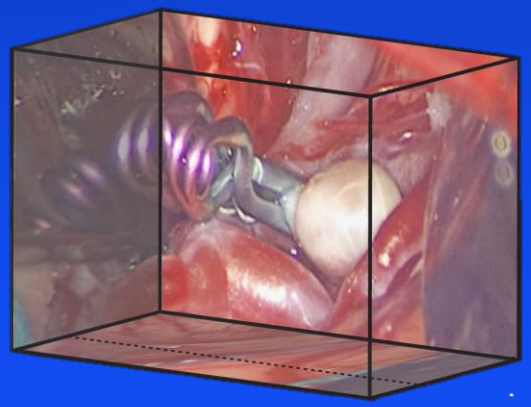

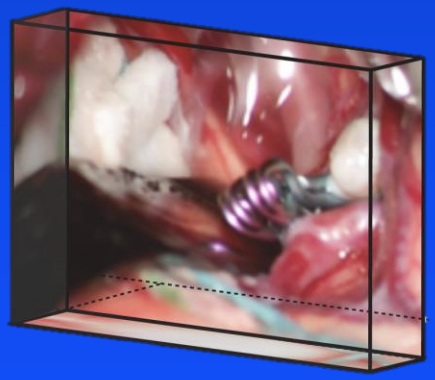

Surgical Adjuncts

- High resolution T2 axial and coronal MRI images
- Intraop navigation
- DTI/tractography
- Intra-operative monitoring
- Ultrasound

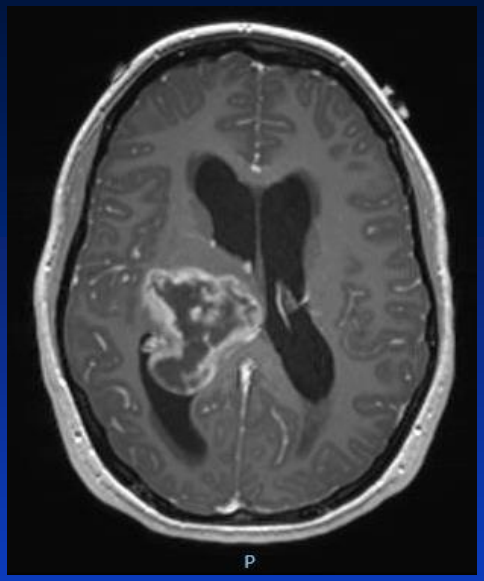

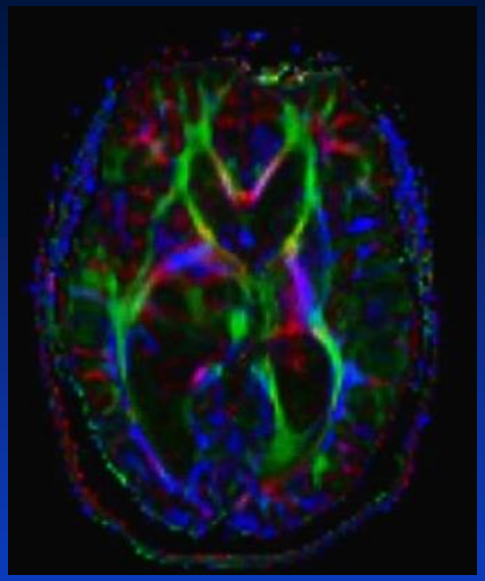

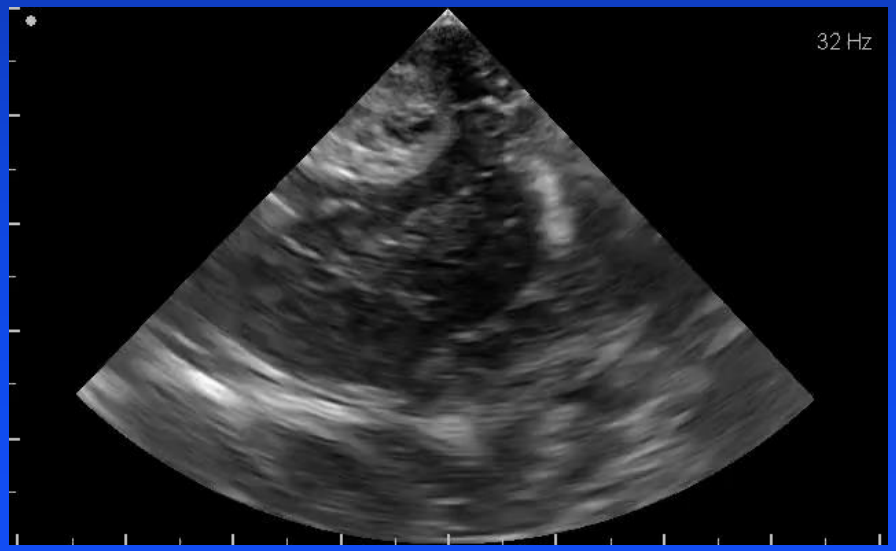

Tubular-Based Tumor Resection – Case 1

- CC: right UE/LE weakness
- HPI: 22 yo RH female presented with progressive right sided weakness
- PE: RUE/RLE 4-/5
- Concerning areas
  - Cortical: Broca's, motor
  - Subcortical: SLF/AF, IFOF (anterior limb), FAT, internal capsule

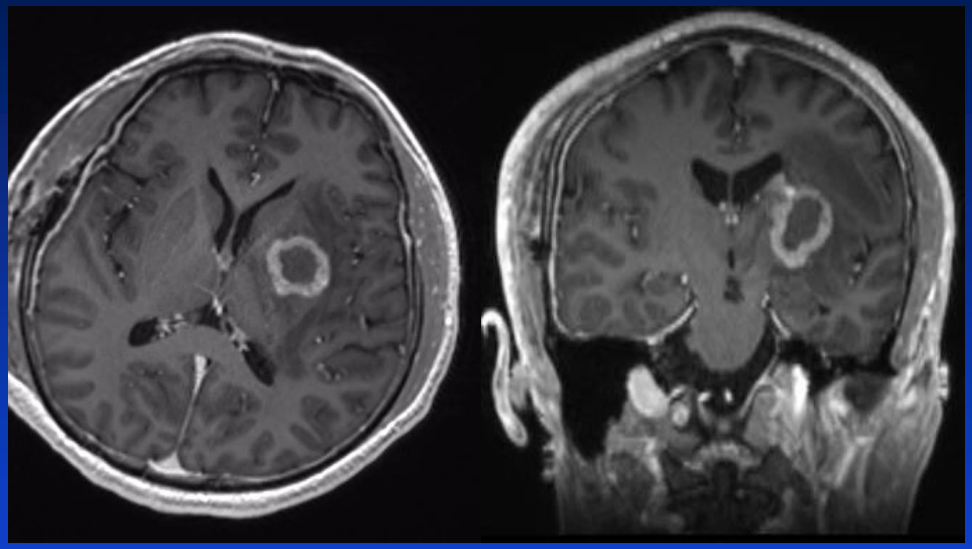

Chaichana et al, *JNS-A*, 178, 2017.
Iyer et al, *J Neurosurg*, 2018, in press

Tubular-Based Tumor Resection – Case 1

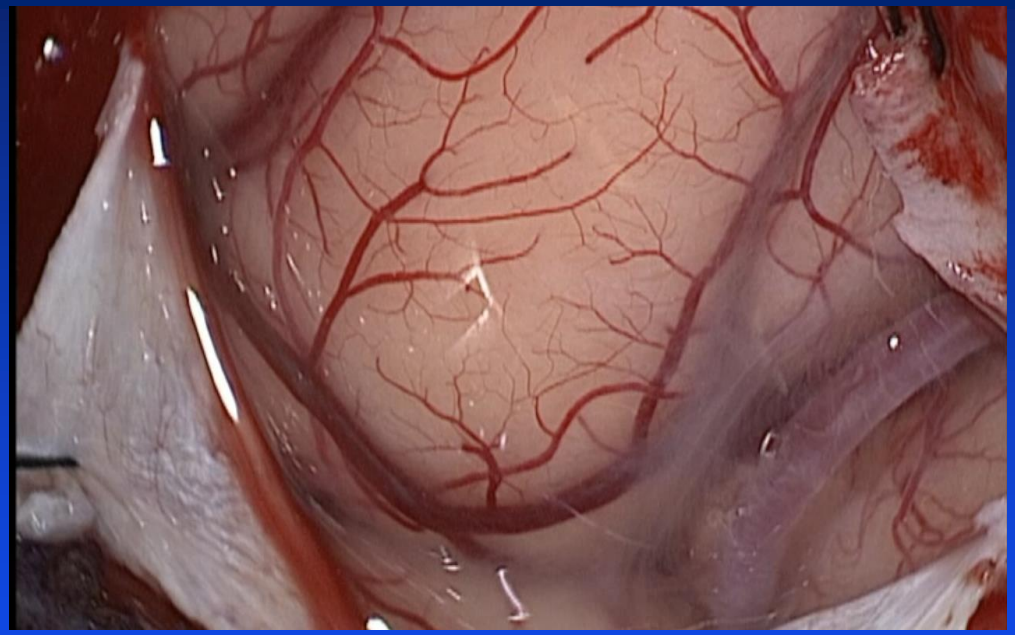

MAYO CLINIC

Chaichana et al, *JNS-A*, 178, 2017
Iyer et al, *J Neurosurg*, 2018, in press

Tubular-Based Tumor Resection – Case 1

- Pathology: Glioblastoma (MGMT+/IDH-)
- Disposition: Home on POD 3 (18 months out without recurrence), neuro intact
- 6 mo – competing in archery competitions

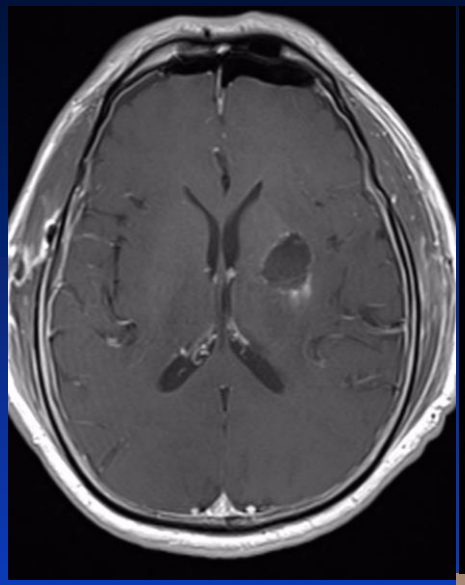

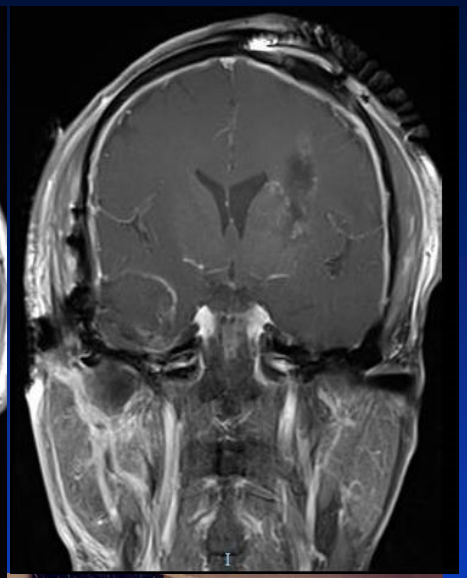

Chaichana et al, *JNS-A*, 178, 2017
Iyer et al, *J Neurosurg*, 2018, in press

Tubular-Based Tumor Resection – Case 2

- CC: right weakness
- HPI: This is a 53 year-old RH male presented with progressive right upper and lower extremity weakness.
- PE: 1/5 RUE/RLE
- Concerning areas:
  - Cortical: motor cortex, sensory cortex
  - Subcortical: SLF/AF, IFOF, thalamus, basal ganglia, internal capsule

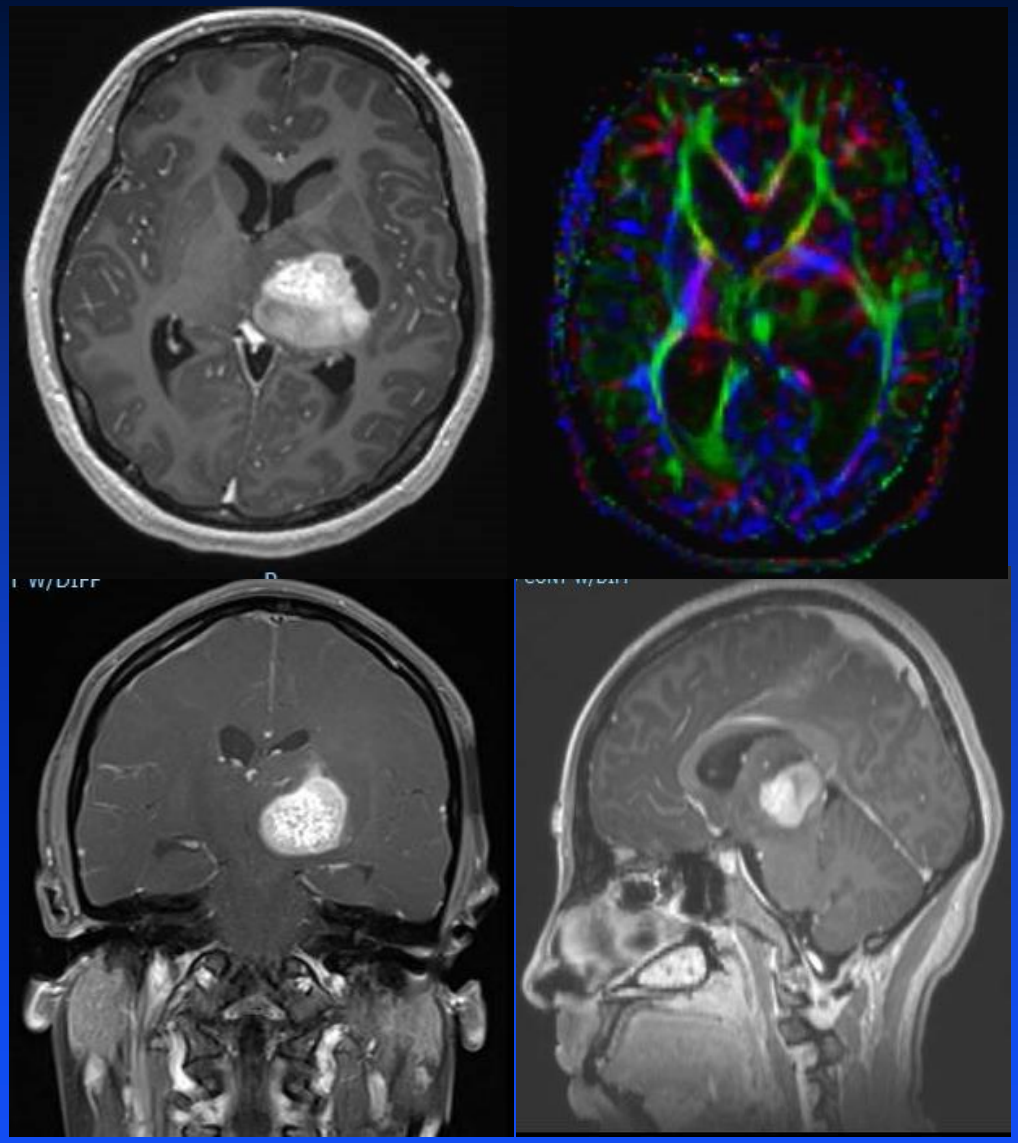

Chaichana et al, *JNS-A*, 178, 2017
Iyer et al, *J Neurosurg*, 2018, in press

Tubular-Based Tumor Resection – Case 2

- Pathology: glioblastoma (MGMT-/IDH-)
- Post-op 4/5 strength, discharged to home on POD 3
- No recurrence at 7 months, slight left drift

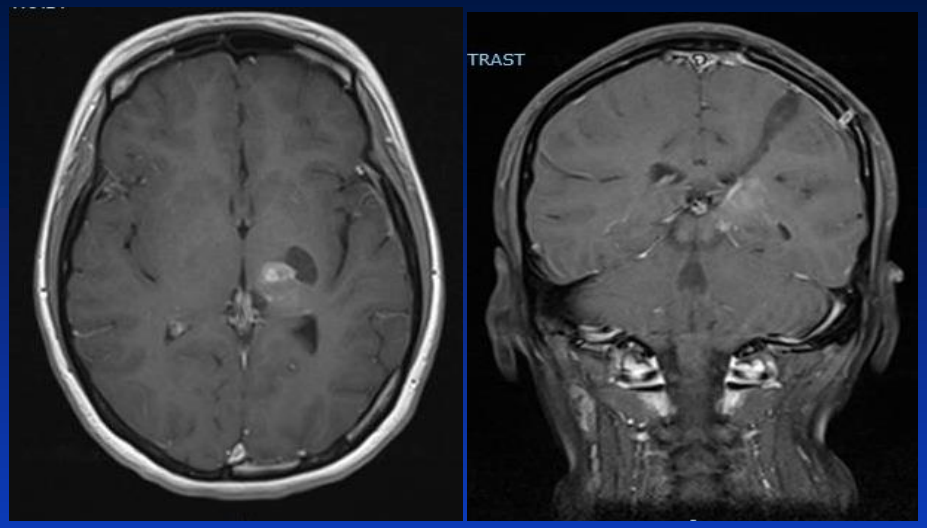

MAYO CLINIC

Chaichana et al, *JNS-A*, 178, 2017
Iyer et al, *J Neurosurg*, 2018, in press

Tubular-Based Tumor Resection – Case 3

- CC: left sided weakness
- HPI: This is a 32 yo RH male presented left hemiparesis
- PE: LUE/LLE 1-2/5
- Concerning areas:
  - Cortical: motor cortex, sensory cortex
  - Subcortical: CST

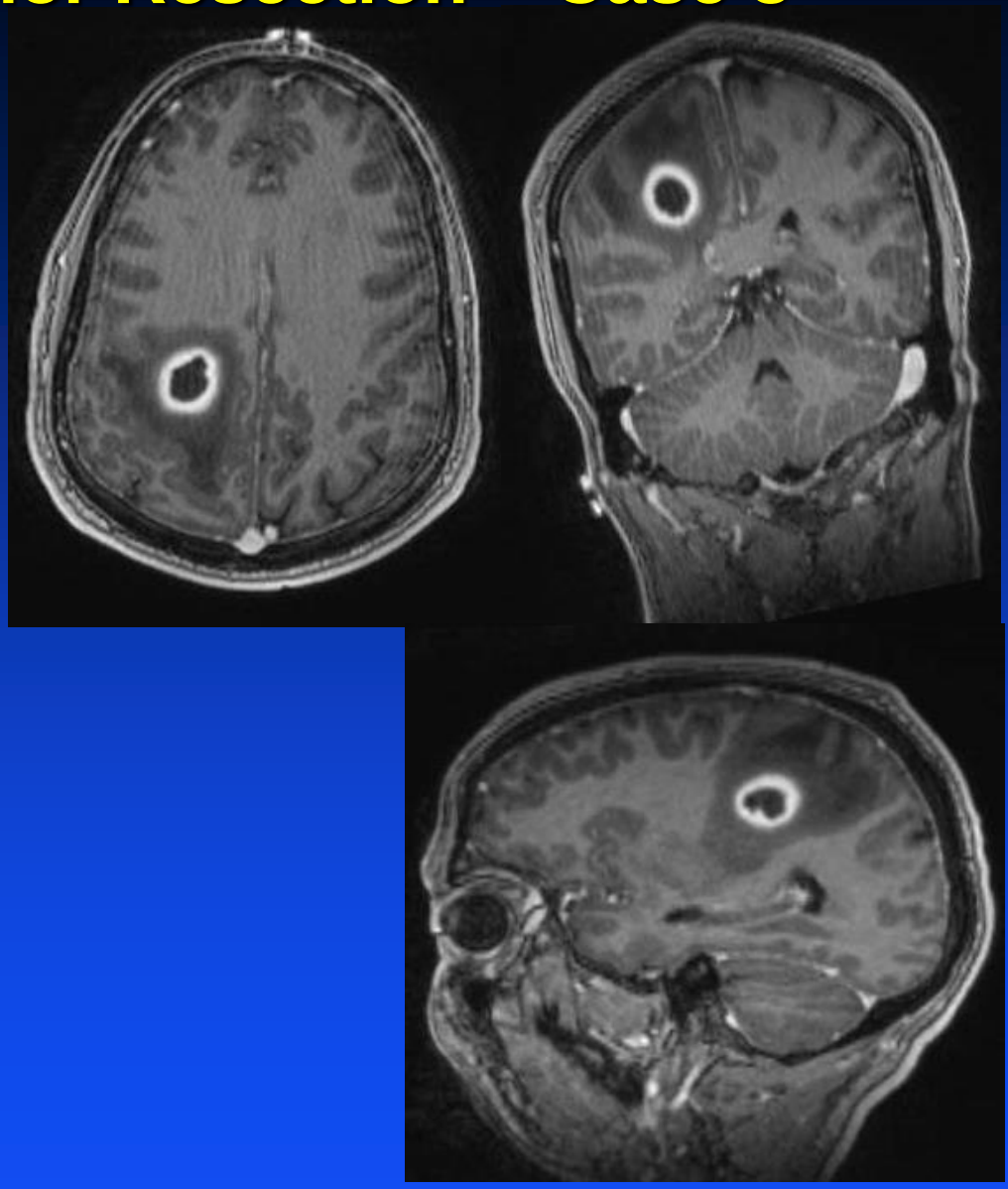

Chaichana et al, *JNS-A*, 178, 2017.
Iyer et al, *J Neurosurg*, 2018, in press

Tubular-Based Tumor Resection – Case 3

- Pathology: GBM
- Disposition: Neuro intact, Discharged to home on POD3
- No recurrence at 8 months

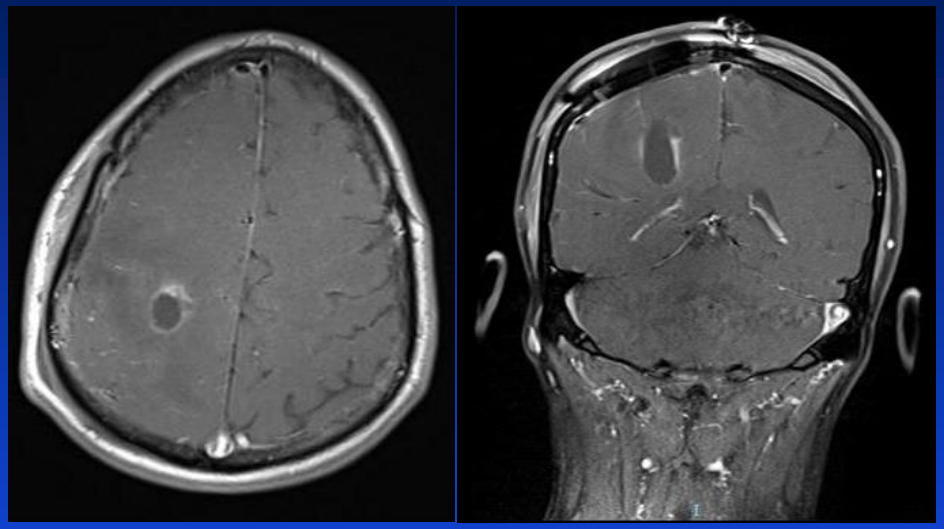

Chaichana et al, *JNS-A*, 178, 2017.
Iyer et al, *J Neurosurg*, 2018, in press

Tubular-Based Tumor Resection – Case 4

- CC: persistent emesis
- HPI: This is a 49 yo female who presented with persistent nausea and vomiting on two previous occasions from two hemorrhages of a right middle cerebellar peduncle cavernoma
- PE: neuro intact except right facial (HB1-2/6) and CNVI weakness

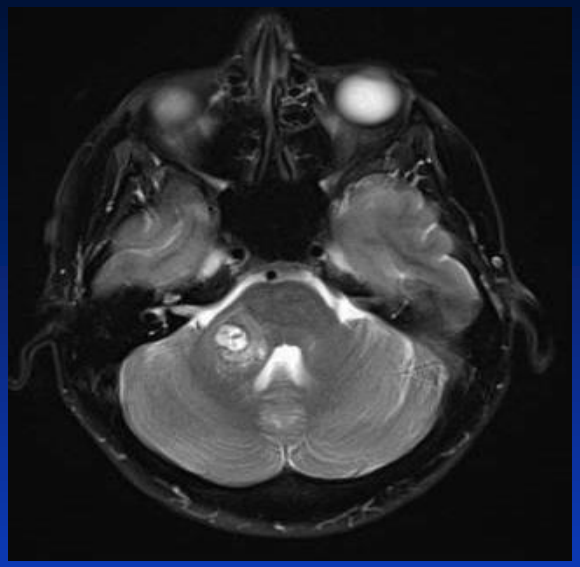

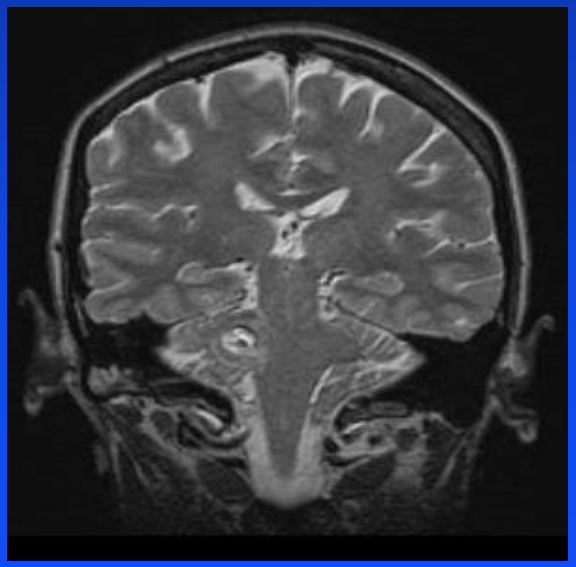

Tubular-Based Tumor Resection – Case 4

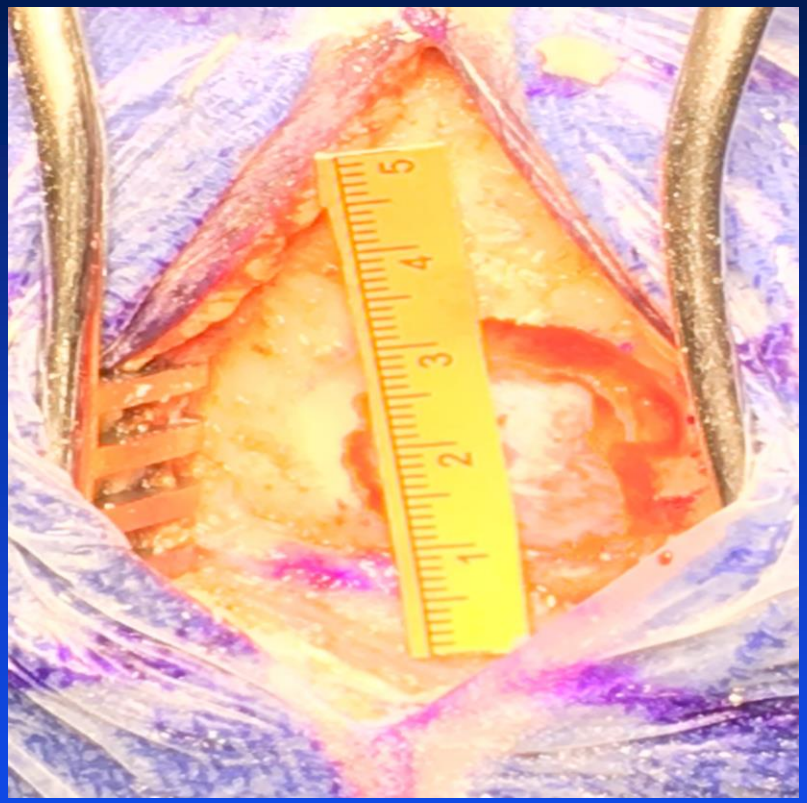

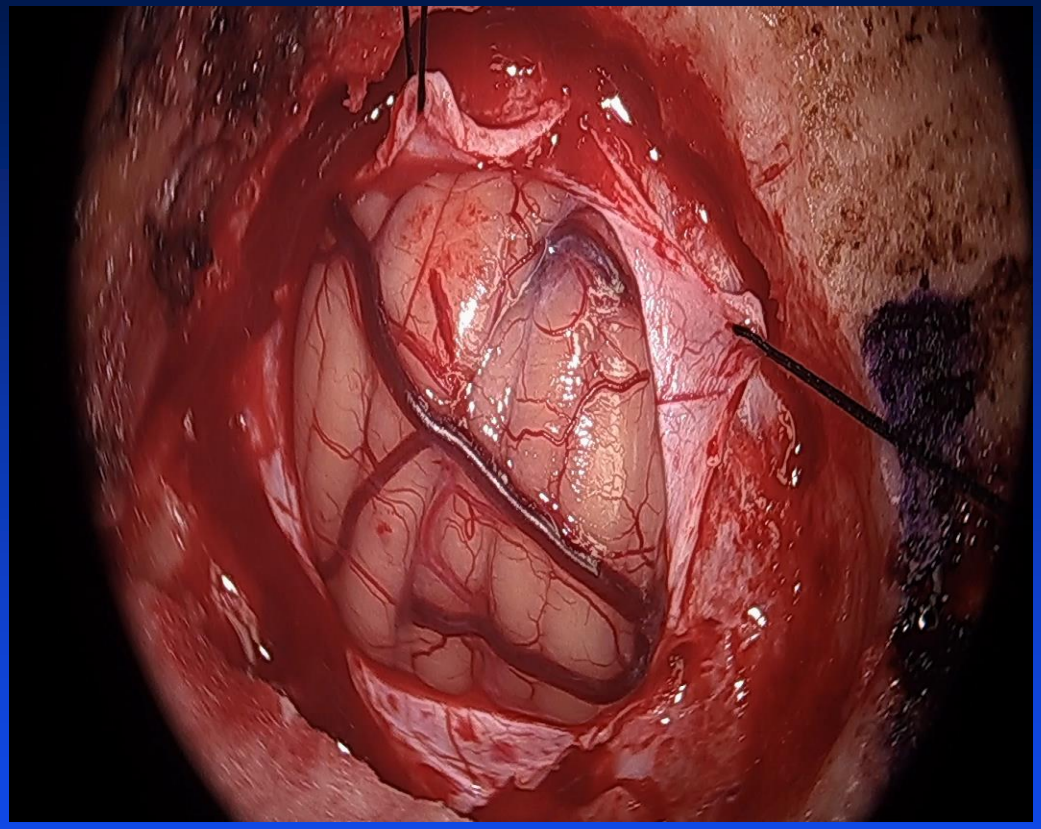

Tubular-Based Tumor Resection – Case 4

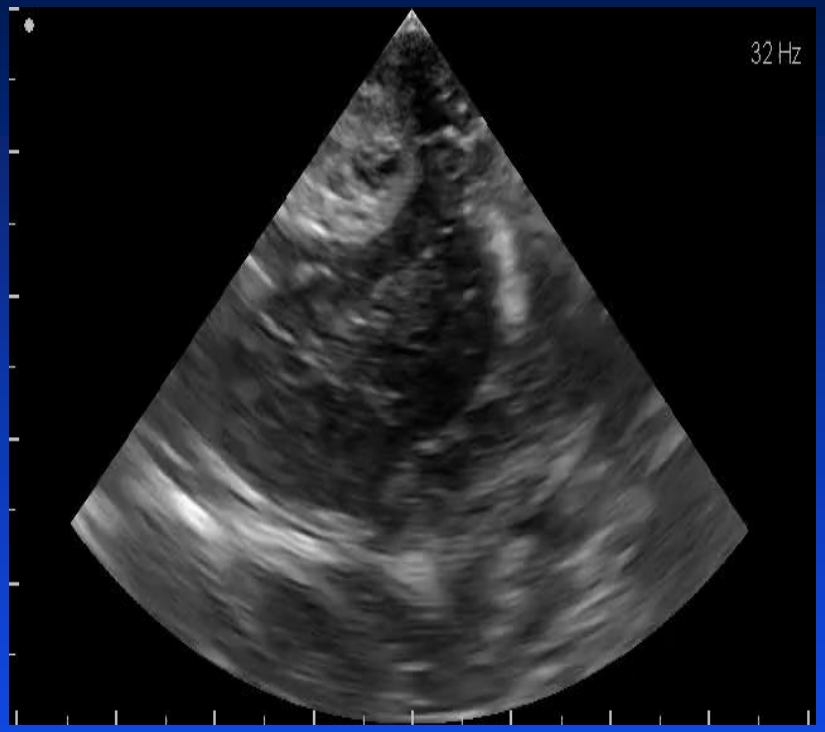

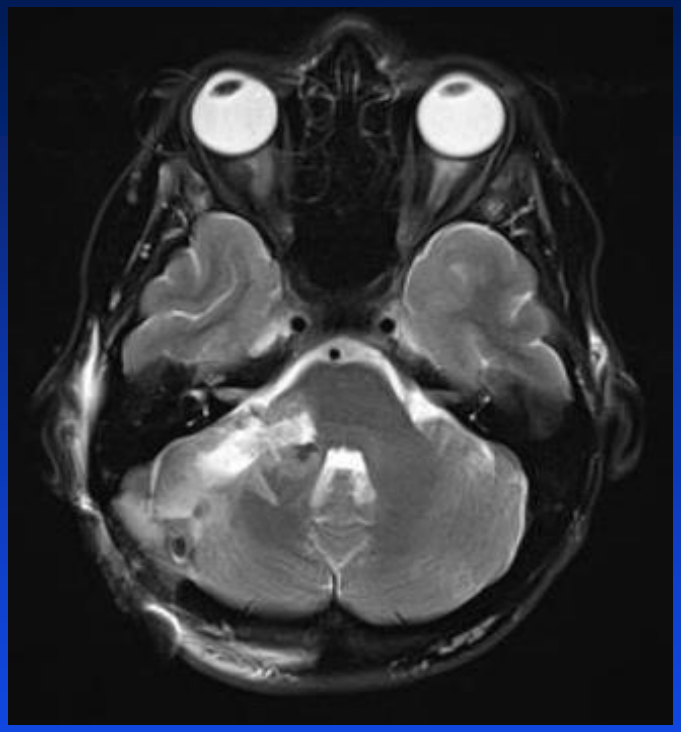

- Pathology: cavernoma
- Disposition: Neuro intact, discharged to home on POD2

BrainPath Brain Tumor Case Totals - 53

- Surgery
  36 resections
  17 excisional biopsies

- Locations
  Thalamus/basal ganglia - 24
  Centrum semiovale/white matter tracts - 16
  Optic pathways 4
  Deep cerebellar nuclei – 8

- Pathology
  GBM/AA - 30
  Metastatic - 10
  Low grade glioma - 2
  Cavernoma - 8
  Other - 2

- Outcomes
  Improved - 39
  Stable – 10
  Worsened – 3 (2 transient)

Conclusions

- Neurological function beyond the standard neurological exam is important to preserve
- Need to understand where the white matter tracts are and what they do
- You can either identify and avoid, or work around or displace these tracts
- Critical to be able to do both, which require a different set of tools